

# Spontaneous Hemomediastinum Due to Thyroid Artery Aneurysm. A Rare Case Report

Gradica F, Xhemalaj D, Sina A, Argjiri D, Lisha L, Kokici F, Gradica F, Rexha V, Gradica K\*

University Hospital Shefqet Ndroqi, Tirana-Albania  
Pharmaceutical Public Service, Tirana, Albania

**Corresponding Author:** Fadil Gradica, University Hospital Shefqet Ndroqi, Tirana-Albania, E-mail: fadil\_gradica68@hotmail.com

**Received:** 📅 April 07, 2020; **Accepted:** 📅 April 13, 2020; **Published:** 📅 April 20, 2020

## Abstract

Spontaneous Hemomediastinum is a rare pathological disorder. Multiple underlying causes and contributory factors can be identified, such as trauma, malignancy, iatrogenic, bleeding disorder or mediastinal organ hemorrhage.

Using contrast enhanced computed tomography (CT) of the chest, hemomediastinum can be adequately diagnosed.

Spontaneous hemomediastinum may occur due to multiple and contributory causes such as: secondary to hemorrhagic disorders, mediastinal tumors or after sudden increase in intrathoracic pressure, (e.g. during coughing, sneezing or vomiting, or sudden sustained hypertension) [1, 2].

In this case report, a 76-year-old male is presented with of thyroid artery aneurysm resulting in hemomediastinum causing thoracic pain.

**Keywords:** Spontaneous; Haemomediastinum; Pain; Aneurism; Thyroid Artery.

## Introduction

Spontaneous hemomediastinum is rarely observed in clinical practice and is a potentially life-threatening condition. Underlying causes have been categorized into three groups. First, spontaneous hemomediastinum may occur secondary to bleeding disorders such as hemophilia, or secondary to anticoagulant treatment. Secondly, mediastinal tumors (e.g. thymomas, teratomas), organs or blood vessels may be involved.

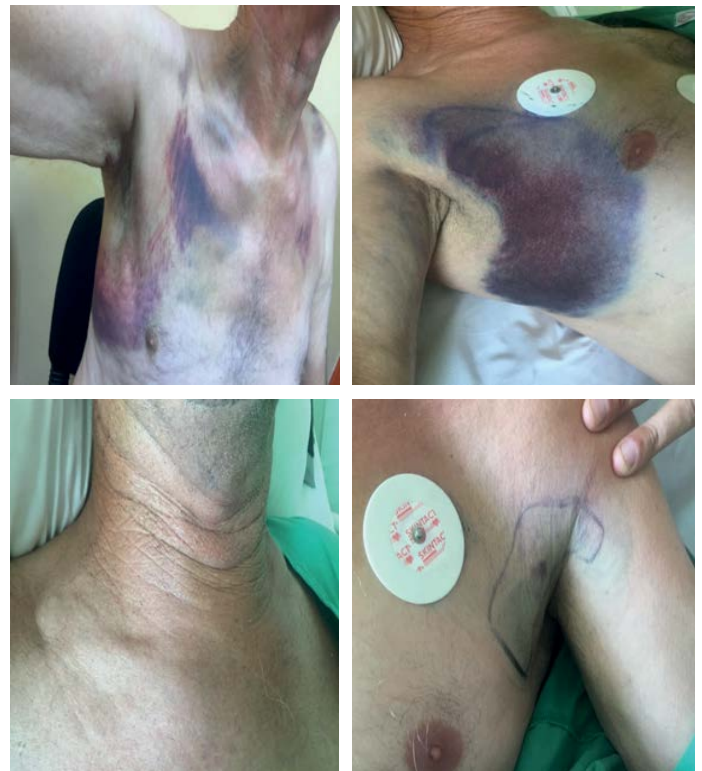## Case report

In this case report, a 65- year-old male treated for diabetes mellitus type II, for a long time, and used irregular medications presented in the emergency room with a suddenly syncopal condition, dyspnea, and edema of the cervical region, severe thoracic pain. He also mentioned complaints of heart burn and dysphagia, while he was working.

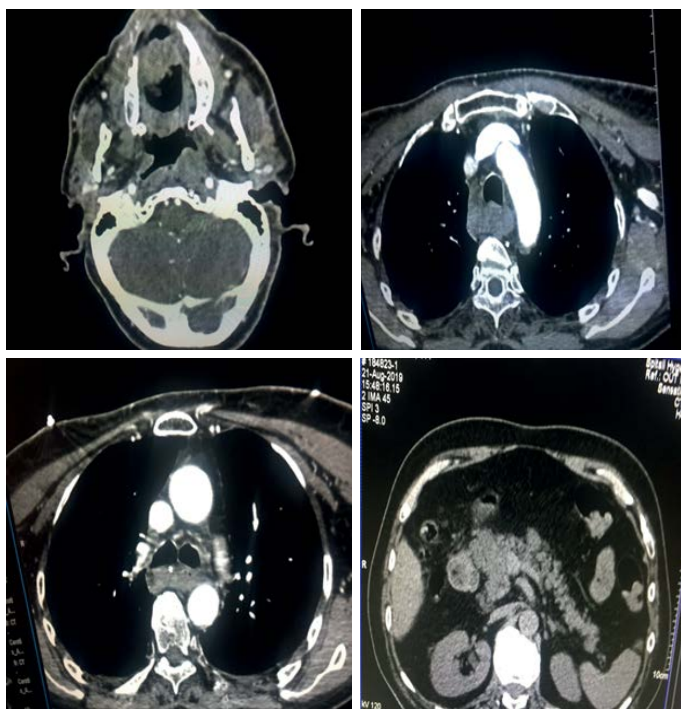
In the inspection of the patient, huge ecchymosis and hematomas of the antero-lateral chest wall were presented. (Figure 1).

After multidisciplinary team, the patient was sent to the intensive care unit, under mechanic ventilation.

After CT examination and of thyroid artery aneurysm resulting in hemomediastinum causing thoracic pain.



**Figure 1.** Edema and Gauge Hematoma of the Patient at the Emergency Room



**Figure 2.** After CT Examination and Of Thyroid Artery Aneurysm Resulting in Haemomediastinum Causing Thoracic Pain

A contrast-enhanced chest CT was performed, which ruled out a pulmonary embolism, but did reveal a huge mass hemorrhagic mass in the mediastinum.

Laboratory blood testing showed normal kidney and liver function, normal coagulation, a normal blood count and negative cardiac enzymes.

Due to respiratory distress because of upper airway compression, an endotracheal intubation was lifesaving and avoided tracheotomy in the unit of intensive care.

Transcatheter embolization was performed with super selective catheterization of thyroid artery.

The patient recovered quickly and was discharged ten days after the procedure. Six weeks later, upon evaluation at the outpatient clinic, he was free of complaints and chest CT showed that the mediastinal hematoma had completely resolved.

## Discussion

Haemomediastinum occurs mostly because of aneurysms and pseudoaneurysms of the pulmonary vasculature which affect the pulmonary arteries than the bronchial arteries or the pulmonary veins [3, 4, 5].

An aneurysm typically involves all 3 layers of the vessel wall, whereas a pseudoaneurysm represents a contained rupture in which not all layers of the affected wall are involved. [6].

High success rates have been reported for bronchial artery embolization, but recurrence after Successful embolization can occur probably due to collateral vessels, incomplete embolization, and arterial re-canalization making re-intervention necessary [3, 4, 7, 8, 9].

A true aneurysm of the thyroid artery is extremely rare [7]

Surgical ligation and/or excision and endovascular emboliza-

tion were reported as possible treatments for this rare disease [8].

In order to adequately diagnose a hemomediastinum, performing a chest CT with contrast material application is the designated approach. Consecutive angiography may then be the best step towards treatment.

## Conclusion

A hemomediastinum is a rare pathological event with several possible underlying causes including a ruptured bronchial artery aneurysm.

Thyroid artery aneurysms present with various symptoms ranging from massive hemoptysis to subtle chest pain.

First choice treatment consists of transcatheter embolization.

## References

1. Kazunori I, Masakazu Y (2015) A case of spontaneous thymic hemorrhages. *The Journal of the Japanese Association for Chest Surgery*, 29: 852-855. [Crossref]
2. Li X, Liu L, Cao D, et al. (2016) Spontaneous Hematoma of Posterior Mediastinum with an Uncommon Cause: A Case Report and Review of the Literature. *Clin Pract* 6: 838. [Crossref]
3. Kim JS, Lee SY, Son KH, et al (2015) Bronchial Artery Aneurysm Presenting as Hematemesis and Mediastinal Hemorrhage. *Korean J Thorac Cardiovasc Surg* 48: 298-301. [Crossref]
4. Seo Y, Kwak J (2011) Spontaneous hemomediastinum and hemothorax caused by a ruptured bronchial artery aneurysm. *Korean J Thorac Cardiovasc Surg* 44: 314e7. [Crossref]
5. Quero Valenzuela F, Piedra Fernández I, Sevilla López S (2011) Cueto-Ladrón de Guevara A. Spontaneous hemomediastinum and hemothorax after dissecting bronchial artery aneurysm. *Interact Cardiovasc Thorac Surg* 12: 619e21. [Crossref]
6. Osiro S, Wear C, Hudson R, et al. (2012) A friend to the airways: a review of the emerging clinical importance of the bronchial arterial circulation. *Surg Radiol Anat* 34: 791e8. [Crossref]
7. Restrepo C, Carswell A (2012) Aneurysms and pseudoaneurysms of the pulmonary vasculature. *Semin Ultrasound CT MRI* 33: 552e66. [Crossref]
8. Tanaka K, Ihaya A, Horiuchi T, et al. (2003) Giant mediastinal bronchial artery aneurysm mimicking benign esophageal tumor: a case report and review of 26 cases from literature. *J Vasc Surg* 38: 1125e9. [Crossref]
9. Thomas ML, Ammar AD (2000) True aneurysm of the thyrocervical trunk: case report and literature review. *Ann Vasc Surg* 14: 677-678. [Crossref]
10. Selcuk D, Kantarci F, Akgul S, et al. (2006) Partially thrombosed fusiform inferior thyroid artery true aneurysm mimicking a thyroid nodule. *J Ultrasound Med* 25: 805-808. [Crossref]